



# Rapid spread of a neurovirulent strain of HSV-1 through the CNS of BALB/c mice following anterior chamber inoculation

Nancy M Archin and Sally S Atherton

University of Texas Health Science Center at San Antonio, Department of Microbiology, San Antonio, Texas, USA, and Medical College of Georgia, Department of Cellular Biology and Anatomy, Augusta, Georgia, USA

Following unocular anterior chamber (AC) inoculation of BALB/c mice with the KOS strain of herpes simplex virus type 1 (HSV-1), virus spreads from the injected eye to the ipsilateral suprachiasmatic nucleus (SCN) in the central nervous system (CNS) to infect the optic nerve and retina of the contralateral eye, and mice develop retinitis in that eye only. In contrast, after AC inoculation of BALB/c mice with the H129 strain of HSV-1, mice develop bilateral retinitis. The pathway(s) by which H129 spreads to cause bilateral retinitis is not known. To determine the route and timing of H129 spread after AC inoculation, BALB/c mice were injected in the AC of the right eye with  $5 \times 10^3$  PFU of H129. Brains from 30 mice were sectioned on a brain matrix and the amount of virus in the brain and eyes was determined by plaque assay. Frozen sections were prepared from the eyes, brain, and trigeminal ganglia of an additional 30 mice, and HSV-1 antigen was detected by immunohistochemistry. After AC inoculation, H129 follows a pathway similar to KOS in the CNS, but H129 appears to spread more rapidly than KOS within the CNS. Unlike KOS, H129 is able to infect brain stem nuclei and H129-infected mice developed neurological impairments in addition to bilateral retinitis. The results of these studies suggest that the ability of H129 to spread rapidly in the CNS allows early virus infection of retino-recipient nuclei proximal to the contralateral and ipsilateral optic nerves. Early infection of retino-recipient nuclei, such as the SCN may allow virus to spread into the retinas before a virus-specific immune response can be induced. *Journal of NeuroVirology* (2002) 8, 122–135.

**Keywords:** herpes simplex virus type 1; immunohistochemistry; retinitis; central nervous system; neurovirulence

## Introduction

Acute retinal necrosis syndrome (ARN) is a potentially devastating retinal disease, which usually affects predominantly healthy individuals of all ages (Lewis *et al*, 1989; Duker *et al*, 1990; Azazi *et al*, 1991; Culbertson *et al*, 1991; Thompson *et al*, 1994; Ganatra

*et al*, 2000; Lee and Charles, 2000). ARN is characterized by necrotizing retinitis, vitritis, retinal arteritis, optic neuropathy, and retinal vasculitis (Fisher *et al*, 1982; Sergott *et al*, 1989; Culbertson and Atherton, 1993). The disease can be unilateral or bilateral with involvement of the second eye occurring within a few months to as long as 34 years after onset of ARN in one eye (Falcone and Brockhurst, 1993; Ezra *et al*, 1995; Schlingemann *et al*, 1996). Several members of the human herpes virus family, notably herpes simplex virus type 1 (HSV-1), type 2 (HSV-2), and varicella zoster virus (VZV) have been implicated as causes of ARN (Lewis *et al*, 1989; Duker *et al*, 1990; Azazi *et al*, 1991; Culbertson *et al*, 1991; Thompson *et al*, 1994; Ganatra *et al*, 2000; Lee and Charles, 2000). Although cytomegalovirus (CMV) has been implicated in a few

---

Address correspondence to Sally S Atherton, Medical College of Georgia, Department of Cellular Biology and Anatomy, Augusta, GA 30912-2000, USA. E-mail: satherton@mail.mcg.edu

This study was supported by the National Eye Institutes of Health fellowship EY06753 (NMA) and National Institutes of Health grant EY06012 (SSA).

Received 30 July 2001; revised 30 October 2001; accepted 7 December 2001.

cases of ARN, CMV-related ARN is a rare occurrence (Silverstein *et al*, 1997; Akpek *et al*, 1999; Ganatra *et al*, 2000). In 1924, Von Szily showed that inoculation of HSV-1 into one eye of rabbits leads to uveitis and retinopathy in the contralateral or uninoculated eye only (Von Szily, 1924). Features of retinal destruction in the rabbit model mimic those observed in human patients with ARN.

More recently it was reported that unioocular anterior chamber (AC) inoculation of BALB/c mice with the KOS strain of HSV-1 results in retinitis in the uninoculated eye only (Whittum *et al*, 1984; Atherton and Streilein, 1987; Vann and Atherton, 1991). Although the anterior segment of the inoculated eye is infected, the retina of this eye is spared. Following AC inoculation with KOS, virus travels through the central nervous system (CNS) to infect the retina of the uninoculated eye via synaptically connected neurons. Virus leaves the inoculated eye via the parasympathetic fibers of cranial nerve III, which supply the iris and ciliary body (Whittum-Hudson and Pepose, 1987; Margolis *et al*, 1989; Vann and Atherton, 1991). By day 3 postinoculation (p.i.), virus spreads to the ipsilateral Edinger–Westphal nucleus (EW) of the hypothalamus. From the EW, virus travels to the ipsilateral suprachiasmatic nucleus (SCN), which becomes infected at day 5 p.i. (Vann and Atherton, 1991). From the ipsilateral SCN, virus then infects the optic nerve and the retina of the contralateral eye by day 7 p.i. (Vann and Atherton, 1991). Although the contralateral SCN becomes virus positive by day 7 p.i., virus does not enter the ipsilateral optic nerve and retina and these structures remain free of virus throughout the course of infection (Bosem *et al*, 1990; Vann and Atherton, 1991; Azumi and Atherton, 1994).

In contrast to KOS, when H129, a neurovirulent and highly neuroinvasive strain of HSV-1, is injected into the AC of BALB/c mice, the mice develop bilateral retinitis (Vann, 1992). H129 was originally isolated from a patient with fatal encephalitis and has been described elsewhere (Dix *et al*, 1983). Experimental studies have shown that neuroinvasive and nonneuroinvasive strains of herpes simplex virus differ in their ability to produce neurologic and ocular diseases (Wander *et al*, 1980; Richards *et al*, 1981; Dix *et al*, 1983; Stroop and Schaefer, 1986; Stroop and Schaefer, 1987; Stroop and Schaefer, 1989). Some of these differences may be partially attributed to strain-dependent abilities of virus to invade and replicate within specific sites in neurological and ocular tissues (Richards *et al*, 1981; Dix *et al*, 1983; Stroop and Schaefer, 1986; Stroop and Schaefer, 1989). Consequently, the pathways by which neuroinvasive and nonneuroinvasive strains spread to cause ocular or CNS diseases may be different. This difference is not limited to herpes simplex virus. Neuroinvasive and nonneuroinvasive strains of other  $\alpha$ -herpesvirus, such as pseudorabies virus, have also been shown to spread differently in CNS and ocular tissues (Card

*et al*, 1991, 1992). Because the pathways by which neuroinvasive and nonneuroinvasive strains of herpes simplex virus spread to cause ocular or CNS diseases may differ, and because unlike KOS, H129 is a neuroinvasive and neurovirulent strain of HSV-1 (Dix *et al*, 1983), we hypothesized that, following AC inoculation, H129 follows a different pathway in the CNS than KOS to cause bilateral retinitis. Alternatively, H129 and KOS follow similar pathways in the CNS after AC inoculation, but H129 is able to infect retino-recipient nuclei such as the SCN earlier than KOS. Infection of retino-recipient nuclei proximal to the ipsilateral and contralateral optic nerve early during infection may allow H129 access to the retinas before a virus-specific immune response develops. The purpose of these studies was to determine the route and timing of virus spread following unioocular AC inoculation of the H129 strain of HSV-1.

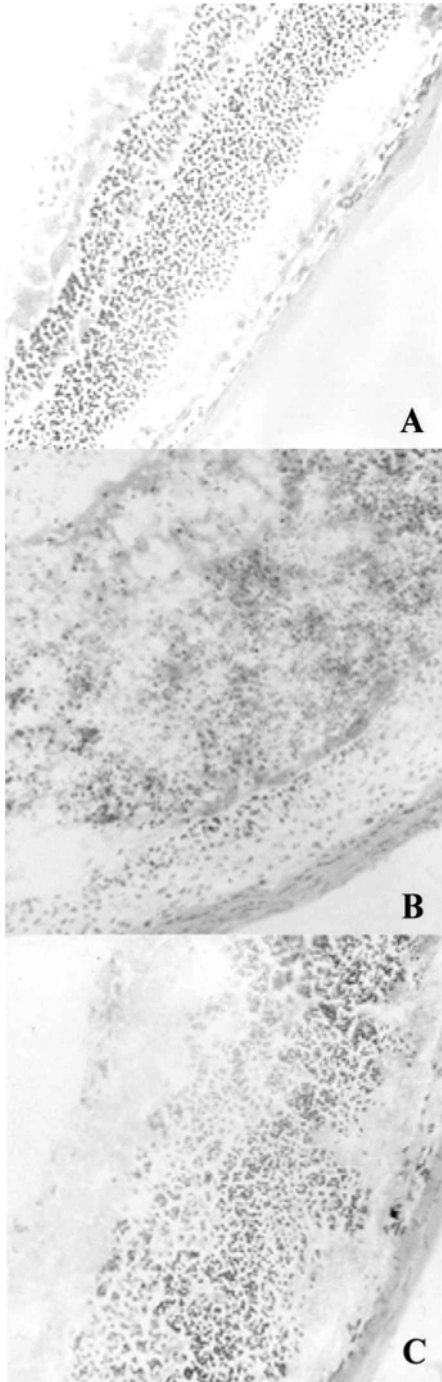
## Results

### *Clinical findings*

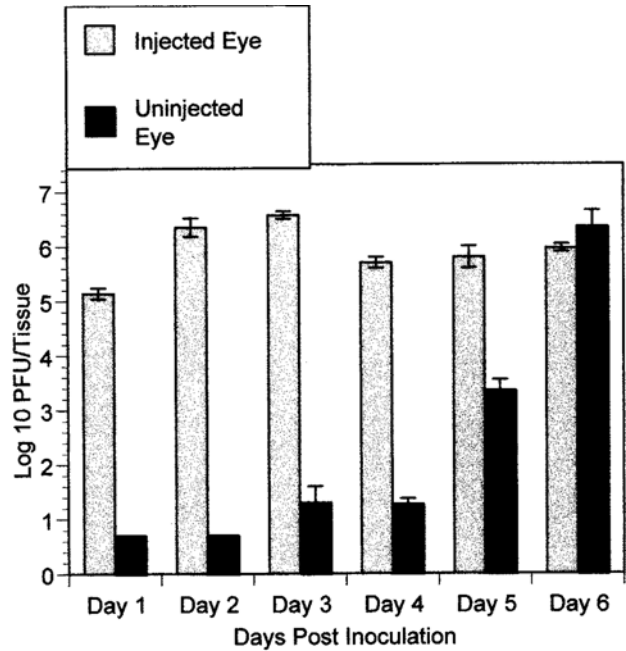
Following AC inoculation with H129, all mice developed bilateral retinal necrosis by day 7 p.i., characterized by destruction of retinal architecture and infiltration of inflammatory cells (Figure 1). Phthisis of the injected eye was observed in several mice. Severe neurological impairments were also observed in mice during the course of infection. By day 4 or 5 p.i., 90% of H129-injected mice exhibited signs of neurological disease, such as ruffling of the fur and weight loss. By day 6 p.i., mice were severely wasted, ataxic, and dysstatic. Infected mice also showed other signs of acute neurological illnesses such as kyphosis and hemiparesis. Because 40–60% of infected mice were moribund by day 7 p.i., day 6 was chosen as the end point for studies of spread of H129 following AC inoculation.

### *Quantification of virus in infected areas by plaque assays*

**Eyes** Following unioocular AC inoculation of  $5 \times 10^3$  PFU of H129, the titer of virus in the injected eye reached a maximum at day 2 p.i., decreased slightly at day 4 p.i., and remained relatively constant throughout the remainder of the course of infection (Figure 2). As shown in Figure 2, virus was not recovered from the contralateral (uninoculated) eye on day 1 or 2 p.i. Although a small amount of virus (approximately  $2 \times 10^1$  PFU) was recovered from the contralateral eye at days 3 and 4 p.i., virus could not be detected by immunohistochemistry (Figure 3B). Atherton and Streilein observed two waves of virus in the contralateral eye following AC inoculation of BALB/c mice with KOS (Atherton and Streilein, 1987). The first wave of virus was of low titer and detected 24–48 h p.i. A second wave of virus of high titer was detected at day 7 p.i. Our studies suggest that H129 may also invade the contralateral eye in two



**Figure 1** Photomicrograph showing retinal necrosis at day 7 p.i. in mice infected via the AC with H129. BALB/c mice were inoculated in the AC with  $2 \mu\text{l}$  of  $5 \times 10^3$  PFU of H129 virus or an equivalent volume of tissue culture media (mock-infection). Mice were sacrificed at day 7 p.i., and the eyes were collected. Frozen sections were prepared and stained with hematoxylin and eosin. The retinal architecture of mock-infected mice remained intact (A), whereas the architecture of the retina of the ipsilateral (B) and contralateral (C) eyes of virus-infected mice was destroyed (original magnification,  $\times 198$ ).

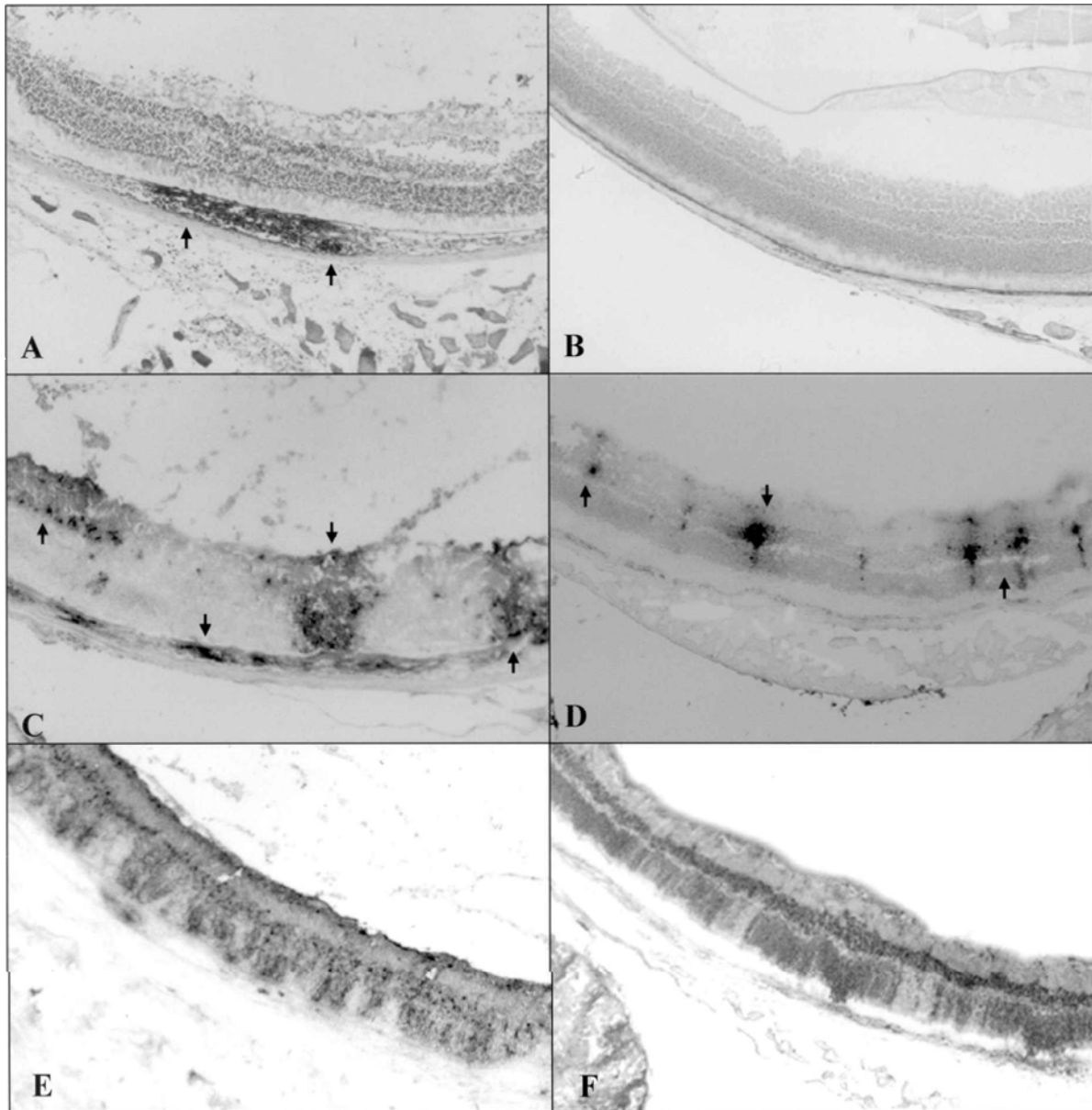


Minimum level of detection is 0.7 log PFU/tissue

**Figure 2** Titers of infectious virus (average PFU  $\pm$  S.E.M.) in the eyes of BALB/c mice after AC inoculation of H129. Mice were inoculated in the AC of the right eye with  $5 \times 10^3$  PFU of virus. Five mice were sacrificed on each day indicated. The eyes from each mouse were collected, homogenates were prepared, and titers of virus were determined by plaque assays as described in Materials and methods. Virus titers from each sample were determined in duplicate. The minimum level of detection (0.7 log PFU/tissue) represents the limit of the sensitivity of the plaque assays.

separate waves. The small amount of virus detected in the contralateral eye at days 3 and 4 p.i. may be analogous to the first wave of virus observed in KOS-infected mice. The location of this first wave of virus in H129-infected mice remains to be determined. By day 6 p.i., the titer of virus in the uninoculated eye was comparable to that observed in the injected eye.

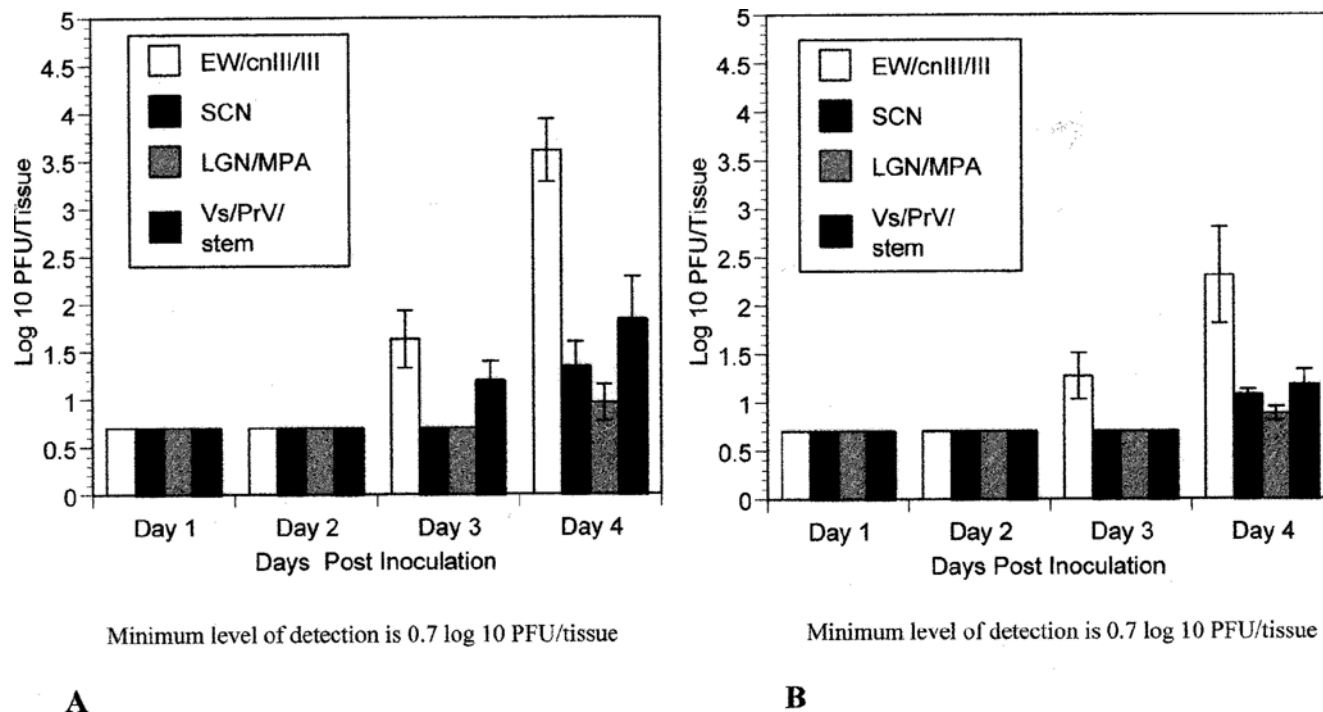
**Brain** To determine the early spread of H129 through the CNS, virus recovery studies were performed on brain sections ipsilateral and contralateral to the side of ocular injection. At days 1 and 2 p.i., virus was not recovered from any area of either the ipsilateral or the contralateral brain (Figures 4A and 4B). At day 3 p.i., virus was recovered from the ipsilateral oculomotor nerve and its roots (CnIII), the ipsilateral oculomotor nucleus (III), and the ipsilateral Edinger–Westphal nucleus (Figure 4A). Although virus was also recovered from the same areas of the contralateral brain (Figure 4B), the average titer of virus in the contralateral side was slightly less than that observed for the ipsilateral side ( $1.85 \times 10^1$  PFU versus  $4.24 \times 10^1$  PFU). At day 3 p.i., virus was also recovered from the ipsilateral sensory root of the trigeminal nerve (sV) and the principal sensory trigeminal nucleus (PrV) of the brain



**Figure 3** Ipsilateral and contralateral retinas on days 4–6 after AC inoculation with H129 into euthymic BALB/c mice. BALB/c mice were inoculated with  $5 \times 10^3$  PFU of H129 into the AC of right eye. Five mice were sacrificed each day and immunohistochemistry was performed on tissues using a polyclonal anti-HSV-1 antibody. Tissues were then examined for the presence or absence of virus antigen. (A) Ipsilateral retina at day 4 p.i. Black arrows indicate virus antigen in the choroid. (B) Contralateral retina at day 4 p.i. Virus was not detected in the contralateral retina in any mice at day 4 p.i. (C) Ipsilateral retina at day 5 p.i. Positive-stained cells were seen in all layers of the retina as well as the choroid (black arrows). (D) Contralateral retina at day 5 p.i. Virus-positive cells were first observed in the contralateral retina at day 5 p.i. (black arrows). All layers of the retina were infected, but the amount of viral antigen observed was less than that seen in the ipsilateral eye. The choroid of the contralateral eye did not become infected at any time during the course of infection. (E) Ipsilateral retina and (F) contralateral retina at day 6 p.i. The entire retina of both the ipsilateral and contralateral eye is infected (original magnification,  $\times 99$ ).

stem but not from the contralateral portion of these areas. Beginning on day 4 p.i., virus was recovered from both the ipsilateral and contralateral SCN. The average titer of virus recovered from the ipsilateral SCN was slightly higher than that of the contralateral SCN ( $2.24 \times 10^1$  PFU versus  $1.21 \times 10^1$  PFU). At day 4 p.i., a small amount of virus (approximately  $1 \times 10^1$  PFU) was also recovered from both the ipsilateral and

contralateral medial pretectal areas (MPA) and the lateral geniculate nucleus (LGN). At day 4 p.i., virus was also recovered from the contralateral sensory root of the trigeminal nerve and the principal sensory trigeminal nucleus of the brain stem. As shown in Figures 4A and 4B, as infection progressed, the titer of virus in the brain increased. For these studies virus titers were only obtained for days 1–4 p.i. After



**Figure 4** Titers of infectious virus (average PFU  $\pm$  S.E.M) in the brain of BALB/c mice after AC inoculation of H129. Mice were inoculated in the AC of the right eye with  $5 \times 10^3$  PFU of virus. Five mice were sacrificed on each day. The brain from each mouse was collected and dissected on a brain matrix, homogenates were prepared, and titers of virus were determined by plaque assays as described in Materials and methods. Virus titers for each sample were determined in duplicate. The minimum level of detection (0.7 log PFU/tissue) represents the limit of the sensitivity of the plaque assays. (A) Ipsilateral brain. (B) Contralateral brain. Abbreviations: EW, Edinger-Westphal nucleus; cnIII, root entry zone of cranial nerve 3 (oculomotor nerve); III, nucleus of the oculomotor nerve; SCN, suprachiasmatic nucleus; LGN, lateral geniculate nucleus; MPA, medial pretectal area; Vs, sensory root of cranial nerve 5 (trigeminal nerve); PrV, primary sensory nucleus of the trigeminal nerve; stem, brain stem. EW/cnIII/III = oculomotor complex. Vs/PrV/stem = trigeminal nerve complex.

day 4 p.i., the number of nuclei positive for HSV-1 antigen (as observed by immunohistochemistry) increased exponentially. Therefore after day 4 p.i., the amount of virus in a single nucleus could not be determined accurately by virus recovery studies.

### Timing of virus infection and distribution of viral antigen

As described in Materials and methods, frozen sections of eyes, brain, and trigeminal ganglia from H129-injected BALB/c mice sacrificed on successive days p.i. were stained for HSV-1 antigen.

#### Days 1 and 2

**Eyes** At day 1 p.i., virus was detected in the iris and ciliary body of the anterior segment of the injected eye only (Table 1). At day 2 p.i., the intensity of antigen staining in the anterior segment of the injected eye increased (not shown). In addition, the ipsilateral ciliary ganglion also became positive for viral antigen on day 2 p.i. and remained positive throughout the course of infection (Table 1). The posterior segment of the injected eye remained virus negative in all but one mouse in which a small area in the choroid was viral antigen positive (not shown).

Virus was not detected in the contralateral eye at day 1 or day 2 p.i.

**Trigeminal ganglia** A few virus-infected cells were detected in the ipsilateral trigeminal ganglion in 2 of 5 mice at day 2 p.i. Viral antigen was not detected in the contralateral trigeminal ganglion at day 2 p.i. (Table 1).

**Brain** A few virus-positive cells were observed in the area of the ipsilateral oculomotor nerve and its roots in 2 of 5 mice examined at day 2 (Table 1). Virus was not detected at any other sites in the brain at day 2 p.i.

#### Days 3 and 4

**Eyes** At days 3 and 4 p.i., virus-infected areas were observed within the choroid of the injected eye of all mice examined (Figure 3A, Table 1). At day 4 p.i., a few scattered virus-positive cells were also observed in the ganglion cell layer of the peripheral ipsilateral retina (directly posterior to the ciliary body) in 2 of 5 mice (not shown). The ipsilateral optic nerve of one mouse also contained a few virus-positive fibers (not shown). However the central retina of all mice was virus-negative at day 4 p.i. (Figure 3A). Virus was not detected in any area of the contralateral eye at this time (Figure 3B, Table 1).

**Table 1** Sites of virus infection following AC inoculation of H129<sup>a</sup>

Tissue <sup>b</sup>	Site	Days p.i.					
		1	2	3	4	5	6
Eye <sub>i</sub>	Iris, Ciliary body	+	++	+++	+++	+++	+++
	Choroid	-	+/- (1)	++	++	++	++
	Optic nerve	-	-	-	+/- (1)	++	+++
Ganglia	Retina	-	-	-	+/- (2)	++	+++
	CG <sub>i</sub>	+	++	++	++	++	++
	CG <sub>c</sub>	-	-	-	-	-	-
	TG <sub>i</sub>	-	+/- (2)	+	++	++	++
Brain	TG <sub>c</sub>	-	-	-	-	+/- (2)	+
	EW, III, cNIII <sub>i</sub>	-	+/- (2)	++	+++	+++	+++
	EW, III, cNIII <sub>c</sub>	-	-	+/- (1)	+	++	+++
	SCN <sub>i</sub>	-	-	-	++	++	+++
	SCN <sub>c</sub>	-	-	-	+	++	+++
	LGN <sub>i</sub>	-	-	-	-	++	+++
	LGN <sub>c</sub>	-	-	-	-	++	+++
	MPA <sub>i</sub>	-	-	-	+	++	+++
	MPA <sub>c</sub>	-	-	-	+	++	+++
	PrV, V <sub>s<sub>i</sub></sub>	-	-	+	+	++	+++
	PrV, V <sub>s<sub>c</sub></sub>	-	-	-	+/- (1)	++	+++
	SC <sub>i</sub>	-	-	-	+/- (1)	++	+++
	SC <sub>c</sub>	-	-	-	-	++	+++
	Eye <sub>c</sub>	Iris, Ciliary body	-	-	-	-	-
Choroid		-	-	-	-	-	-
Optic nerve		-	-	-	-	+	++
Retina		-	-	-	-	++	+++

<sup>a</sup>BALB/c mice were inoculated with  $5 \times 10^3$  PFU of H129 into the AC of right eye. Five mice were sacrificed each day and immunohistochemistry was performed on tissues using a polyclonal anti-HSV-1 antibody. Tissues were then examined for the presence or absence of virus antigen.

<sup>b</sup>The pattern of antigen expression in tissue sites is indicated as follows: (-), no antigen detected; (+/-), sparse amount of antigen detected in 1 or 2 mice (number of mice are in parentheses); (+), sparse amount of antigen detected in all mice; (++) , moderate amount of antigen detected in all mice; (+++) , dense amount of antigen detected in all mice. CG, ciliary ganglion; EW, Edinger–Westphal nucleus; III, oculomotor nucleus; cNIII, root entry zone of cranial nerve 3; LGN, lateral geniculate nucleus; MPA, medial pretectal area; PrV, principal sensory trigeminal nucleus; SC, superior colliculus; SCN, suprachiasmatic nucleus; TG, trigeminal ganglion; Vs, sensory root of trigeminal nerve. Subscripts: (C), contralateral, left side; (I), ipsilateral, right side.

**Trigeminal ganglia** At days 3 and 4 p.i., all of the ipsilateral trigeminal ganglia were virus-positive; virus was not detected in the contralateral trigeminal ganglion at this time (Table 1).

**Brain** At day 3 p.i., many virus-positive cells were detected in the ipsilateral oculomotor nerve and its roots, the ipsilateral oculomotor nucleus and the ipsilateral EW (Figure 5A). The contralateral oculomotor nucleus of one mouse was also positive (not shown). At day 3 p.i., a few virus-positive cells were also observed in the ipsilateral sensory root of the trigeminal nerve and the primary sensory trigeminal nucleus (Figure 6C). Virus was not observed in the contralateral sV and PrV of any of the mice at day 3 p.i. Beginning at day 4 p.i. virus was observed in both the ipsilateral and the contralateral SCN (Figure 5B), and more virus positive cells were observed in the ipsilateral SCN than the contralateral SCN. At day 4 p.i. a few virus-positive cells were also observed in the contralateral and ipsilateral MPA.

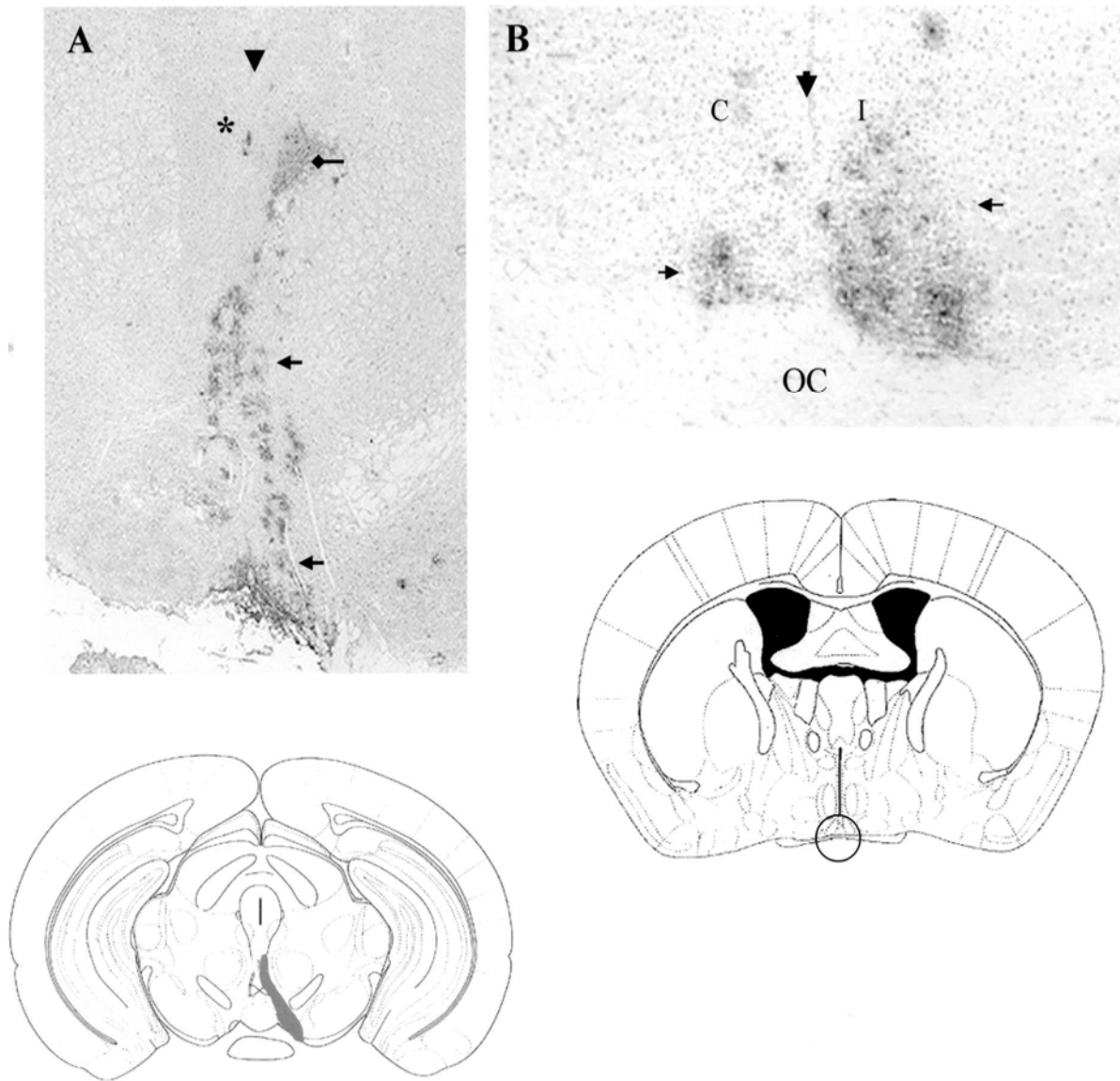
*Days 5 and 6*

**Eyes** At day 5 p.i., virus was detected in the optic nerve and retina of the injected eye of all mice (Figure 3C, Table 1). At this time, virus was also

detected for the first time in the contralateral optic nerve and retina (Figure 3D). Virus was not observed in the anterior segment or the choroid of the contralateral eye at any time during infection nor was virus observed in the contralateral ciliary ganglion. In both retinas, virus appeared to spread from the ganglion cell layer (initial site of virus infection in the retina) to the outer nuclear and photoreceptor cell layers. At day 6 p.i., the intensity of antigen staining in both the ipsilateral and contralateral retinas increased (Figures 3E and 3F), and both retinas were becoming necrotic.

**Trigeminal ganglia** On days 5 and 6 p.i., many virus-positive cells were detected in the ipsilateral trigeminal ganglion, but only a few positive cells were detected in the contralateral trigeminal ganglion (Table 1).

**Brain** At day 5 p.i., many virus-positive cells were detected in both the ipsilateral and contralateral LGN (Figures 6A and 6B). Many virus-positive cells were also observed in the ipsilateral and contralateral MPA (not shown). By day 6 p.i., most nuclei synaptically connected to sites of infection in the brain were virus-positive. In addition, contiguous and related nuclei of the ipsilateral and contralateral brain were also infected with virus, suggesting that



**Figure 5** Coronal sections of infected brain tissues following AC inoculation with H129. BALB/c mice were inoculated with  $5 \times 10^3$  PFU of H129 into the AC of right eye. Five mice were sacrificed each day and immunohistochemistry was performed on tissues using a polyclonal anti-HSV-1 antibody. Tissues were then examined for the presence or absence of virus antigen. (A) Oculomotor nerve complex at day 3 p.i. Large, vertical black arrow indicates the midline of the brain. Small black arrows indicate virus antigen in the ipsilateral root entry zone of the oculomotor nerve. Diamond arrow indicates the ipsilateral oculomotor nucleus. Asterisk shows the ipsilateral Edinger-Westphal nucleus. Region shaded in gray of coronal brain section schema<sup>a</sup> highlights infected areas depicted in photomicrograph. (B) Ipsilateral (I) and contralateral (C) suprachiasmatic nuclei at day 4 p.i. Large, vertical black arrow indicates the midline of the brain. Small black arrows indicate infected areas. OC, optic chiasma. Region of coronal brain section schema<sup>b</sup> encircled highlights infected areas depicted in photomicrograph (original magnification of (A),  $\times 40$ ; original magnification of (B),  $\times 99$ ).

<sup>a</sup>Adaptation of Bregma  $-3.28$  mm, *The Mouse Brain In Stereotaxic Coordinates* (Franklin and Paxinos, 1997). With permission.

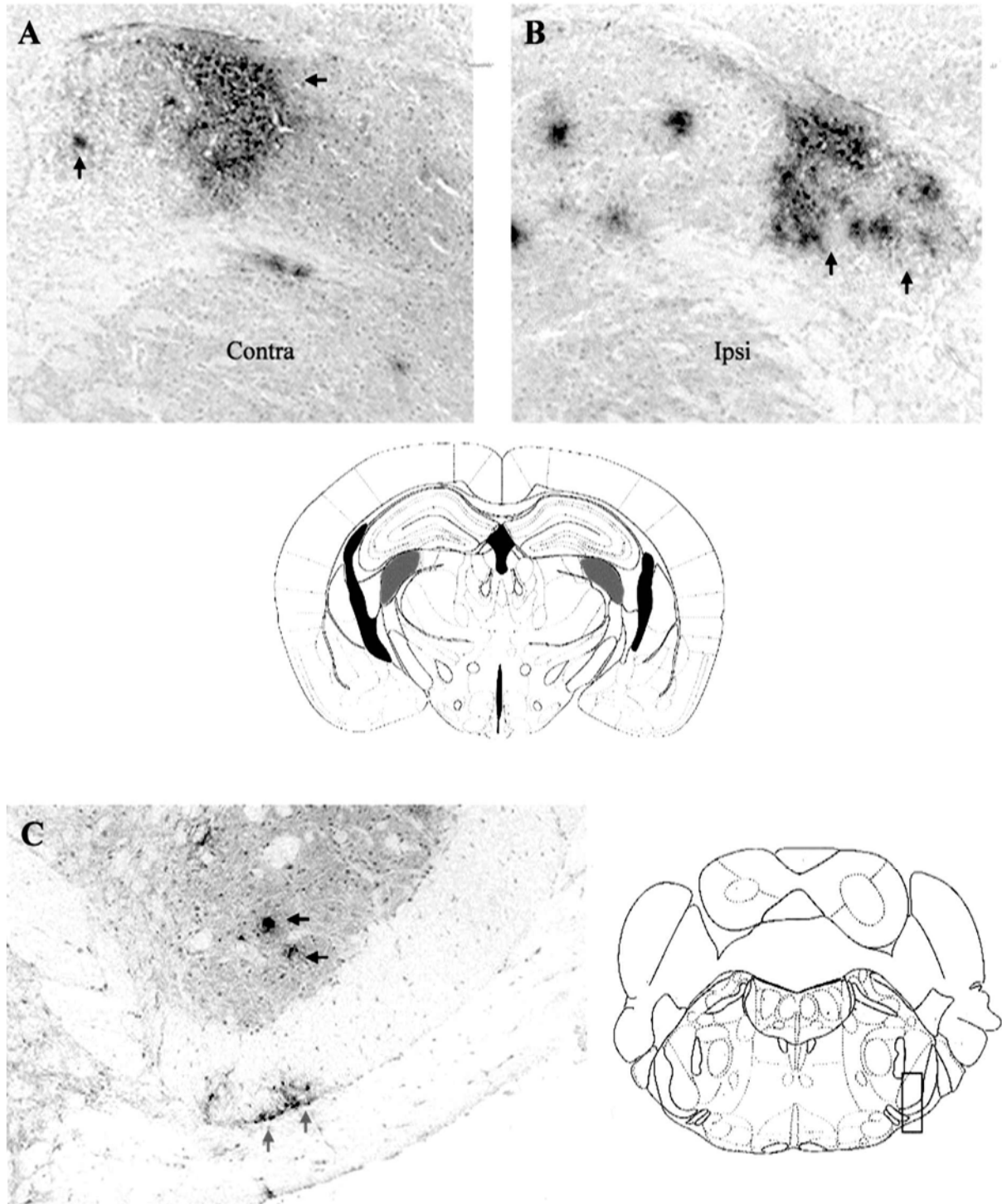
<sup>b</sup>Adaptation of Bregma  $-0.34$  mm, *The Mouse Brain In Stereotaxic Coordinates* (Franklin and Paxinos, 1997). With permission.

H129 spread bilaterally following unocular AC inoculation of virus.

## Discussion

In this study, plaque assays and immunohistochemistry staining for virus antigen were used to determine the pathways by which H129, a highly neurovirulent

strain of HSV-1, spreads and causes bilateral retinitis. Following unocular AC inoculation with H129, virus replicated rapidly to high titers in the injected eye. By day 2 p.i., the titer of virus in the injected eye increased from  $5 \times 10^3$  PFU (amount of virus injected) to an average of  $2.25 \times 10^6$  PFU. Immunohistochemistry staining indicated that most of the virus recovered at day 2 p.i. from the injected eye was in the anterior segment and the ipsilateral ciliary ganglion.



**Figure 6** Coronal sections of infected brain tissues following AC inoculation with H129. BALB/c mice were inoculated with  $5 \times 10^3$  PFU of H129 into the AC of right eye. Five mice were sacrificed each day and immunohistochemistry was performed on tissues using a polyclonal anti-HSV-1 antibody. Tissues were then examined for the presence or absence of virus antigen. (A) Contralateral and (B) ipsilateral lateral geniculate nucleus at day 5 p.i. Black arrows indicate infected areas. Regions of coronal brain section schema<sup>a</sup> shaded in gray highlight infected areas depicted in photomicrograph. Ipsi, ipsilateral; Contra, contralateral. (C) Viral antigen detected in the sensory root of the trigeminal nerve (small gray arrows) and primary sensory trigeminal nucleus (small black arrows) at day 3 p.i. Region of coronal brain section schema<sup>b</sup> enclosed within box highlights infected areas depicted in photomicrograph (original magnification of (A) and (B),  $\times 99$ ; original magnification of (C),  $\times 40$ ).

<sup>a</sup>Adaptation of Bregma  $-2.06$  mm, *The Mouse Brain In Stereotaxic Coordinates* (Franklin and Paxinos, 1997). With permission.

<sup>b</sup>Adaptation of Bregma  $-5.34$  mm, *The Mouse Brain In Stereotaxic Coordinates* (Franklin and Paxinos, 1997). With permission.



By day 3 p.i., virus had also spread to the choroid of the injected eye. However, the retina of the injected eye remained free of virus. On day 3 p.i., virus was also first detected in the ipsilateral oculomotor complex and EW nucleus of the mesencephalon. Because virus-positive cells were not observed in the retina of the injected eye at either day 2 or 3 p.i. and because axons of retinal ganglion cells provide the only output from the retina into the brain (Sefton and Dreher, 1985), virus observed in the oculomotor complex and EW nucleus at day 3 p.i. must have spread from the injected eye via a nonretino-chiasmatic pathway. The result that the ipsilateral ciliary ganglion was virus positive at day 2 p.i. suggests that H129 leaves the injected eye via parasympathetic fibers that innervate the iris and ciliary body and is transported by the oculomotor nerve retrogradely to the oculomotor complex and EW nucleus as has been reported for the KOS strain of HSV-1 (Vann and Atherton, 1991).

Virus-positive cells were also observed in the ipsilateral sensory root of the trigeminal nerve as well as the principal trigeminal sensory nucleus of the brain stem at day 3 p.i. Because a few virus-positive cells were observed in 2 of 5 ipsilateral trigeminal ganglia at day 2 p.i. and because by day 3 p.i. the trigeminal ganglia from all mice were virus-positive, these results suggest that H129 also leaves the injected eye via the branches of the ophthalmic division of the trigeminal nerve that innervate the anterior segment of the eye. As mentioned earlier, H129-infected mice begin to exhibit symptoms of neurological illness, such as ruffling of the fur, at day 4 p.i. During infection the number of virus-infected neurons in the brain stem increased (unpublished observations). So it is likely that spread of H129 from the trigeminal nerve into the brainstem contributes to some of the neurological deficits observed in infected mice. Neurons acutely infected by  $\alpha$ -herpesvirus eventually undergo degeneration (Card *et al*, 1993).

Neuronal cell death together with immune responses to infection may contribute to the neuropathology observed. In KOS, the virus titer in the brain of infected mice peaks at about day 7 and then slowly decreases to the minimum level of detection as virus is cleared from the brain (unpublished observation). Likewise the number of KOS-infected nuclei increases and then slowly decreases (Vann and Atherton, 1991). Although KOS infects the trigeminal ganglion, it does not descend into the brain stem and viral antigen is not observed in brain stem nuclei of KOS-infected mice at any time during infection (Vann and Atherton, 1991). KOS-infected mice do not develop neurological deficits even when virus is present on non-brain stem nuclei of the brain. The ability of H129 to spread into the brain stem and cause neurological disease is not unique to this strain. Other investigators have made similar observations in mice infected with other highly neuroinvasive strains of HSV-1 via the ophthalmic route (Knotts *et al*, 1974; Margolis *et al*, 1989).

Although virus-positive cells were observed mainly in the choroid of the injected eye at day 3 p.i. and at day 4 p.i., a few ganglion cells in the peripheral retina of the injected eye (directly posterior to the ciliary body) were virus-positive in some mice. These results suggest that H129 may be capable of direct anterior to posterior spread in the injected eye. The iris, ciliary body and choroid are innervated by postganglionic parasympathetic fibers from the ciliary ganglion (Wolter, 1960; Marwitt *et al*, 1971; Pillar and Tuttle, 1982). In addition, trigeminal nerve fibers (ophthalmic branch) innervating the iris, ciliary body, and cornea traverse the choroid (Tusscher *et al*, 1989). It is possible that virus spreads via these neuronal connections from the iris/ciliary body complex into the choroid. Because virus was not detected in the central portion of the ipsilateral retina at day 4 p.i., even in areas where the underlying choroid was infected, it appears that virus did not spread from the choroid to the retina. The route by which a few ganglion cells of the peripheral retina became virus positive at day 4 p.i. is less clear but may be due to direct spread of virus from the ciliary body into ganglion cells of the peripheral retina. It is interesting that although virus is replicating in the anterior chamber at very high titers on days 1–3 p.i., virus is detected in only a few ganglion cells in the peripheral retina of 2 mice and the optic nerve of 1 mouse at day 4 p.i. This observation suggests that direct anterior to posterior spread of virus is not the primary pathway by which virus infects the ipsilateral retina.

Virus-infected cells were first observed in both the contralateral and ipsilateral SCN and virus was first recovered from both SCN on day 4 p.i. It has been previously reported that the avian EW nucleus receives direct neuronal input from the SCN (Gamlin *et al*, 1982; Gamlin and Reiner, 1991). Although this pathway has not been described in mice, the results of this study suggest that H129 spread directly from the ipsilateral EW nucleus (which becomes infected at day 3 p.i.) to the ipsilateral SCN. A similar conclusion was drawn for mice infected with KOS via the AC route (Vann and Atherton, 1991). In addition, a few virus-infected cells were also observed in the MPA at day 4 p.i. A projection from the MPA to the EW, believed to be part of the pupillary light reflex, has been reported and a direct pretecto-suprachiasmatic pathway has been defined in rats (Trejo and Cicerone, 1984; Mikkelsen and Vrang, 1994). Therefore, it might be hypothesized that after infecting the EW nucleus, virus spread to the MPA and then to the SCN. However, because the initial detection of virus in the SCN and the MPA was at the same time (day 4 p.i.), it seems unlikely that virus spread from the MPA to the SCN. In H129-infected mice, more virus-positive cells were observed in the ipsilateral SCN than the contralateral SCN at day 4 p.i. Because extensive commissural projections between the SCN have been described (Card *et al*, 1981), it is likely that

virus crossed from the ipsilateral to the contralateral SCN via these projections.

Focal areas of virus-positive cells were first observed in the retina and the optic nerve of the contralateral eye at day 5 p.i. At the same time, many virus-positive cells were detected in the ipsilateral retina and optic nerve. In all cases, retinal ganglion cells were infected first, followed by infection of the inner nuclear layer and photoreceptor cells. It is well documented that subsets of ganglion cells in the retina project directly to the SCN (Pickard, 1982, 1985; Moore *et al*, 1995). It has also been reported in albino rodents that the optic fibers at the level of the SCN are highly crossed so that the retinorecipient nucleus receives predominantly contralateral retinal ganglion cell input (Wenisch, 1976). Therefore, the most likely pathway by which H129 virus spreads from the CNS to the retina of infected mice is via retrograde spread from the ipsilateral SCN to the contralateral retina and from the contralateral SCN to the ipsilateral retina. Although our results suggest that this pathway is most likely the one by which H129 spreads from the CNS to the retina, there are other possible routes. In addition to the SCN, the superior colliculus (SC), the lateral geniculate nuclei (vLGN, dLGN), the intergeniculate leaflet (IGL), and the medial pretectal area (MPA) are all known to receive direct retinal input (Wenisch, 1976; Pickard, 1982, 1985; Norgren and Lehman, 1989; Moore *et al*, 1995). In addition, Hoogland and colleagues suggested the possibility of a direct pathway between the retina and the oculomotor nucleus (Hoogland *et al*, 1985).

Although all the previously mentioned nuclei could be potential sources of virus detected in the retina, in these studies, virus was not detected in the LGN, the IGL, and the SC of all but one mouse until day 5 p.i., coincident with detection of virus in the retina. Therefore, it appears unlikely that virus was able to spread (at least during the first 4 days of infection) from the SC or the LGN to the retina. As mentioned before, a few virus-positive cells were detected in the MPA at day 4 p.i. Although the MPA might be the source of virus in the retina during the first 4 days of infection, the SCN is closer to the retina of either eye and is a more direct route by which virus can spread to the retina early during infection. This idea is supported by studies in which  $\alpha$ -herpesvirus injected directly into the vitreous of mice required 2 to 4 days to spread to the pretectal area (Card *et al*, 1991; Sun *et al*, 1996). Conversely, virus infecting the MPA at day 4 p.i. would be expected to require 2–4 days to reach the retina.

The aim of this study was to define the pathway by which unioocular AC inoculation of the H129 strain of HSV-1 results in bilateral retinitis. As has been reported for the KOS strain of HSV-1 (Vann and Atherton, 1991), H129 left the injected eye via the parasympathetic fibers that supply the iris and ciliary body and spread through the CNS to infect the retina

of the contralateral eye. However unlike KOS, H129 also spread from the CNS to infect the retina of the ipsilateral eye resulting in bilateral retinitis. Furthermore, H129 also spread from the injected eye via the ophthalmic branch of the trigeminal nerve into the trigeminal ganglion and from the ganglion into the brain stem. In addition to developing bilateral retinitis, H129-infected mice also developed neurological impairments. H129 spread through the CNS more rapidly than KOS. For example, H129 virus was detected in the EW nucleus of 2 of 5 mice as early as day 2 p.i., whereas KOS is not detected in the EW until day 3 p.i. (Vann and Atherton, 1991). Furthermore, KOS is not detected in the ipsilateral SCN until day 5 p.i. and the contralateral SCN until day 7 p.i., whereas H129 was detected in both SCN by day 4 p.i. As mentioned before, both KOS and H129 spread from the ipsilateral SCN into the contralateral retina. However, H129 was detected in the contralateral retina at day 5 p.i., whereas KOS is not detected in the contralateral retina until day 7 p.i. (Vann and Atherton, 1991). Although H129 follows a similar pathway through the CNS as KOS and infects mainly the same nuclei, it is possible that H129 infects subsets of neurons within a nucleus that KOS cannot. Although differential infection within a nucleus is an interesting possibility, the methodologies used in these studies are not those that would be used to determine differential infection. Nevertheless, tropism of H129 for subsets of neurons that are synaptically connected to distal sites via shorter neuronal pathways than other subsets might partially explain the observation that H129 spread more rapidly than KOS within the brain.

H129 replicates to higher titers in CNS tissues than KOS (Vann, 1992). It could therefore be postulated that ipsilateral ARN in H129-infected mice is a feature of enhanced local replication rather than rapid spread of virus. For example, at day 5 p.i., the number of cells infected in the SCN of H129-infected mice is higher than in mice infected with KOS (unpublished observation). This would be expected, however, because H129 infects both the ipsilateral and contralateral SCN at day 4 p.i., and KOS is not detected in the ipsilateral SCN until day 5 p.i. and in the contralateral SCN until day 7 p.i. It would be expected that H129 in the SCN at day 4 p.i. would replicate and the number of infected cells would increase by day 5 p.i. Although an increase in the number of virus-infected cells is not observed in the SCN of H129-infected mice until day 5 p.i., virus is already present in both the ipsilateral and contralateral retinas by that day. This suggests that enhanced local replication may not be necessary for the initial spread of virus but may rather contribute to the amount of virus infecting the retinas on later days.

The results presented herein also show that H129 spreads in the CNS in a retrograde manner. This finding contradicts reports that the H129 strain of HSV-1 is capable of only anterograde spread

(Zemanick *et al*, 1991; Barnett *et al*, 1995; Sun *et al*, 1996). However, in these previous reports, the AC was not used as a route of inoculation and differences between routes of virus inoculation may explain why H129 was reported to spread anterogradely only. These results suggest the mode by which H129 spreads in the CNS is dependent upon the route of peripheral inoculation.

In conclusion, the results of these studies suggest that the ability of H129 to spread rapidly from site to site in CNS tissues allows virus to infect retino-recipient nuclei proximal to the contralateral and ipsilateral optic nerve early during infection (i.e., on or before day 4 p.i). Early infection of retino-recipient nuclei such as the SCN may allow virus to spread into the retinas before a significant immune response can be induced. In thymectomized, T-cell-depleted mice, KOS is detected in the ipsilateral SCN a day earlier than in euthymic mice and in the contralateral SCN 2 days earlier, and T-cell-depleted KOS-infected mice develop bilateral retinitis (Azumi and Atherton, 1994; Matsubara and Atherton, 1997). Furthermore, T cells infiltrate the contralateral SCN of KOS-infected euthymic mice two days before virus is detected (Zhao *et al*, 1995). This would suggest that T cells are important and play a role in preventing ipsilateral retinitis in KOS-infected mice, perhaps by limiting or delaying the spread of virus into the contralateral SCN. Therefore, a lack of infiltrating T cells in the SCN of H129-infected mice early during infection may correlate with development of bilateral retinitis. Experiments to address this hypothesis are in progress. To our knowledge, this is the first time the pathway of H129 spread after AC inoculation has been extensively studied. Although rare, herpesvirus-induced ARN syndrome remains a serious disease with the outcome for many patients being blindness. Understanding the mechanisms by which some strains of HSV cause unilateral retinitis while others cause bilateral retinitis perhaps may result in the development of more effective methods for the treatment of ARN or in identification of patients at risk for development of bilateral ARN.

## Materials and methods

### *Virus*

H129, a neurovirulent strain of HSV-1, was used in these studies. H129 was originally isolated from a patient with encephalitis (Dix *et al*, 1983). H129 was received in 1985 (a kind gift from RD Dix, Ph.D., University of Miami School of Medicine, Miami, Florida); this strain of HSV-1 has since been passaged numerous times in cell culture. Stocks of H129 virus were propagated on Vero cells grown in complete Dulbecco's modified Eagle's medium (DMEM) containing 5% fetal bovine serum and antibiotics. The titer of virus stocks was determined by standard

plaque assay on Vero cells and titers were expressed as plaque forming units (PFU) per milliliter. Stocks were stored at  $-70^{\circ}\text{C}$  in 1-ml aliquots, and a fresh aliquot of virus stock was thawed and used for each experiment. The stock of H129 used in these experiments had a titer of  $1.4 \times 10^8$  PFU.

### *Animals*

Adult female BALB/c mice 8–12 weeks old (Taconic, Germantown, NY) were used in all experiments. The mice were housed in accordance with National Institutes of Health guidelines. All mice were maintained on a 12-h light alternating with a 12-h dark cycle and were given unrestricted access to food and water. For all intraocular injections, and perfusions, mice were anesthetized intramuscularly with a cocktail containing 0.08 mg rompam and 0.9 mg ketamine per 25 g body mass.

### *Inoculations*

Mice were anesthetized and inoculated via the AC route as follows: the right eye was proptosed, aqueous humor was removed by paracentesis, and 2  $\mu\text{l}$  containing  $5 \times 10^3$  PFU of virus was injected into the AC with a 30-gauge needle attached to a 100- $\mu\text{l}$  microsyringe (Hamilton, Reno, NV). The inoculum was prepared by diluting virus stock in DMEM containing antibiotics. Control mice were inoculated with 2  $\mu\text{l}$  of either phosphate buffered saline (PBS) or DMEM.

### *Perfusions*

Mice were deeply anesthetized and perfused transcardially with PBS for approximately 3 minutes. Following perfusion, the brain, both eyes, and both trigeminal ganglia were quickly removed, snap frozen on dry ice and stored at  $-70^{\circ}\text{C}$ .

### *Immunohistochemistry*

Frozen tissues were sectioned on a cryostat at a thickness of 8–10  $\mu\text{m}$ , and serial sections were collected on positively charged slides (Fisher Scientific, Pittsburgh, PA). Frozen sections were fixed with acetone, incubated with 0.3% hydrogen peroxide to eliminate endogenous peroxidase, blocked with normal goat serum (Vector Laboratories, Burlingame, CA), and incubated with rabbit anti-HSV-1 polyclonal antibody (Accurate Chemicals, Westbury, NY). Sections were then washed with PBS, incubated with anti-rabbit IgG (Vector Laboratories), washed again, and reacted with avidin-biotin solution (Vector Laboratories). Diaminobenzadine (DAB, Sigma, St. Louis, MO) was used as the chromogen to obtain a final color reaction. The color reaction was intensified by adding 0.04% nickel chloride (Sigma) to the DAB solution. Sections were then counterstained with methyl green (Sigma), dehydrated in a graded ethanol series, cleared with xylenes, coverslipped, and examined microscopically for purple-black-stained cells indicative of virus infection.

### Dissection of brain tissue

Frozen brain tissue was allowed to thaw slightly and placed on a rodent brain matrix (ASI Instruments, Warren, MI) that had been chilled on dry ice. When each brain was partially thawed, it was cut into 14 coronal sections using alcohol-sterilized disposable microtome blades (Accu-Edge blades, Sakura Finetek, Torrance, CA). Each brain section was then sectioned in the midline and the right and left halves of each brain slice were placed in separate sterile tubes containing 500  $\mu$ l of serum-free DMEM with antibiotics. Care was taken to avoid contamination of the specimens during collection and dissection of the brain.

### Plaque assay

Each half of each brain section was homogenized. In addition, each eye was also homogenized in 500  $\mu$ l DMEM containing antibiotics. Each homogenate was serially diluted and plated on Vero cells (American Type Culture Collection, Manassas, VA) that were 80% confluent. Adsorption of virus was carried out for 1 h at 37°C in a CO<sub>2</sub> incubator. Following adsorption, the cells were overlaid with a 1:1 solution of 2X DMEM containing 10% serum and antibiotics and 1% low-melt agarose (Life Technologies, Rockville, MD). After 5 days at 37°C, the cells were fixed with 10% buffered formalin and stained with 0.13% crystal violet (Sigma). Plaques were counted, and the titer

of virus (PFU/sample) was calculated and analyzed using Delta Graph (Delta Point, Inc, Monterey, CA).

### Experimental design

To determine the sites and timing of virus infection, the AC of the right eye of 35 mice was injected with 2  $\mu$ l of inoculum containing  $5 \times 10^3$  PFU of H129. Five control mice were injected with an equivalent volume of PBS or DMEM. On days 1–6 p.i., five mice were perfused each day, and the eyes, brain, and trigeminal ganglia from each mouse were removed and snap frozen. Serial 8–10- $\mu$ m sections were prepared from frozen tissues using a cryostat, and immunohistochemistry was used to determine the sites and timing of virus infection.

To determine the titer of virus in the eyes and different areas of the brain, an additional 35 mice were injected with  $5 \times 10^3$  PFU of H129 via the AC route. Five control mice were injected with an equivalent volume of PBS or DMEM. Five virus-infected mice were perfused on days 1–6 p.i. The eyes and brain from each mouse were collected and snap frozen. Each frozen brain was placed in a cold rodent brain matrix and sectioned into 14 coronal sections. Each brain section was dissected through the midline into right and left halves. Each half of each brain section, and both eyes of each mouse were homogenized. The titer of virus in each sample at each time point was determined by plaque assay on Vero cells.

## References

- Akpek EK, Kent C, Jakobiec F, Caliendo AM, Foster CS (1999). Bilateral acute retinal necrosis caused by cytomegalovirus in an immunocompromised patient. *Am J Ophthalmol* **127**: 93–95.
- Atherton SS, Streilein JW (1987). Two waves of virus following anterior chamber inoculation of HSV-1. *Invest Ophthalmol Vis Sci* **28**: 571–579.
- Azazi EM, Samuelsson A, Linde A, Forsgren M (1991). Intrathecal antibody production against viruses of the herpesvirus family in acute retinal necrosis syndrome. *Am J Ophthalmol* **112**: 76–82.
- Azumi A, Atherton SS (1994). Sparing of the ipsilateral retina after anterior chamber inoculation of HSV-1: Requirement for either CD4+ or CD8+ T cells. *Invest Ophthalmol Vis Sci* **35**: 3251–3259.
- Barnett EM, Evans GD, Sun N, Perlman S, Cassell MD (1995). Anterograde tracing of trigeminal afferent pathways from murine tooth pulp to cortex using herpes simplex virus type 1. *J Neurosci* **15**: 2972–2984.
- Bosem ME, Harris R, Atherton SS (1990). Optic nerve involvement in viral spread in herpes simplex virus type 1 retinitis. *Invest Ophthalmol Vis Sci* **31**: 1683–1689.
- Card JP, Brecha N, Karten HJ, Moore RY (1981). Immunocytochemical localization of vasoactive intestinal polypeptide-containing cells and processes in the suprachiasmatic nucleus of the rat: Light and electron microscopic analysis. *J Neurosci* **1**: 1289–1303.
- Card JP, Rinaman L, Lynn RB, Lee BH, Meade RP, Miselis RR, Enquist LW (1993). Pseudorabies virus infection of the rat central nervous system: Ultrastructural characterization of viral replication, transport and pathogenesis. *J Neurosci* **13**: 2515–2539.
- Card JP, Whealy ME, Robbins AK, Enquist LW (1992). Pseudorabies virus envelope glycoprotein gI influences both neurotropism and virulence during infection of the rat visual system. *J Virol* **66**: 3032–3041.
- Card JP, Whealy ME, Robbins AK, Moore RY, Enquist LW (1991). Two  $\alpha$ -herpesvirus strains are transported differentially in the rodent visual system. *Neuron* **6**: 957–969.
- Culbertson WW, Atherton SS (1993). Acute retinal necrosis and similar retinitis syndromes. *Int Ophthalmol Clin* **33**: 129–143.
- Culbertson WW, Brod RD, Flynn HW, Taylor BC, Lightman DA, Gordon G (1991). Chickenpox-associated acute retinal necrosis syndrome. *Ophthalmology* **98**: 1641–1645.
- Dix RD, McKendall RR, Baringer JR (1983). Comparative neurovirulence of herpes simplex virus type 1 strains after peripheral or intracerebral inoculation of BALB/c mice. *Infect Immun* **40**: 103–112.
- Duker JS, Nielsen JC, Eagle RC, Bosley TM, Granadier R, Benson WE (1990). Rapidly progressive acute retinal necrosis secondary to herpes simplex virus, type 1. *Ophthalmology* **97**: 1638–1643.
- Ezra E, Pearson RV, Etchells DE, Gregor ZJ (1995). Delayed fellow eye involvement in acute retinal necrosis syndrome. *Am J Ophthalmol* **120**: 115–116.

- Falcone PM, Brockhurst RJ (1993). Delayed onset of bilateral acute retinal necrosis syndrome; a 34-year interval. *Ann Ophthalmol* **25**: 373–374.
- Fisher JP, Lewis ML, Blumenkranz MS, Culbertson WW, Flynn HW, Clarkson JG, Gass JD, Norton EW (1982). The acute retinal necrosis syndrome. Part 1: Clinical manifestations. *Ophthalmology* **89**: 1309–1316.
- Franklin KBJ, Paxinos G (1997). *The mouse brain in stereotaxic coordinates*. Academic Press: San Diego, CA.
- Gamlin PD, Reiner A (1991). The Edinger–Westphal Nucleus: Sources of input influencing accommodation, pupilloconstriction, and choroidal blood flow. *J Comp Neurol* **306**: 425–438.
- Gamlin PDR, Reiner A, Karten HJ (1982). Substance P-containing neurons of the avian suprachiasmatic nucleus project directly to the nucleus of Edinger–Westphal. *Proc Natl Acad Sci USA* **79**: 3891–3895.
- Ganatra JB, Chandler D, Santos C, Kuppermann B, Margolis TP (2000). Viral causes of the acute retinal necrosis syndrome. *Am J Ophthalmol* **129**: 166–172.
- Hoogland PV, Vanderkrans A, Koole FD, Groenewegen HJ (1985). A direct projection from the nucleus oculomotorius to the retina in rats. *Neurosci Lett* **56**: 323–328.
- Knotts FB, Cook ML, Stevens JG (1974). Pathogenesis of herpetic encephalitis in mice after ophthalmic inoculation. *J Infect Dis* **130**: 16–26.
- Lee WH, Charles SJ (2000). Acute retinal necrosis following chicken pox in a healthy 4 year old patient. *Br J Ophthalmol* **84**: 667–668.
- Lewis ML, Culbertson WW, Post JD, Miller D, Kokame GT, Dix RD (1989). Herpes simplex virus type 1, a cause of the acute retinal necrosis syndrome. *Ophthalmology* **96**: 875–878.
- Margolis TP, La Vail J, Dawson CR (1989). Selective spread of herpes simplex virus in the central nervous system after ocular inoculation. *J Virol* **63**: 4756–4761.
- Marwitt R, Pilar G, Weakly JN (1971). Characterization of two ganglion cell populations in avian ciliary ganglion. *Brain Res* **25**: 317–334.
- Matsubara S, Atherton SS (1997). Spread of HSV-1 to the suprachiasmatic nuclei and retina in T cell depleted BALB/c mice. *J Neuroimmunol* **80**: 165–171.
- Mikkelsen JD, Vrang N (1994). A direct pretectochiasmatic projection in the rat. *Neuroscience* **62**: 497–505.
- Moore RY, Speh JC, Card JP (1995). The retinohypothalamic tract originates from a distinct subset of retinal ganglion cells. *J Comp Neurol* **352**: 351–366.
- Norgren RB Jr, Lehman MN (1989). Retrograde transneuronal transport of herpes simplex virus in the retina after injection in the superior colliculus, hypothalamus and optic chiasm. *Brain Res Bull* **28**: 393–399.
- Pickard GE (1982). The afferent connections of the suprachiasmatic nucleus of the golden hamster with emphasis on the retinohypothalamic projection. *J Comp Neurol* **211**: 65–83.
- Pickard GE (1985). Bifurcating axons of retinal ganglion cells terminate in the hypothalamic suprachiasmatic nucleus and the intergeniculate leaflet of the thalamus. *Neurosci Lett* **55**: 211–217.
- Pillar G, Tuttle JB (1982). A simple neuronal system with a range of uses: The avian ciliary ganglion. In: *Progress in cholinergic biology: Model cholinergic synapses*. Golberg A, Hanin I (eds). Raven Press: New York, New York, pp 213–247.
- Richards JT, Kern ER, Overall JC Jr, Glasgow LA (1981). Differences in neurovirulence among isolates of herpes simplex virus types 1 and 2 in mice using four routes of infection. *J Infect Dis* **144**: 464–471.
- Schlingemann RO, Bruinenberg M, Wertheim-van Dillen P, Feron E (1996). Twenty years' delay of fellow eye involvement in herpes simplex virus type 2-associated bilateral acute retinal necrosis syndrome. *Am J Ophthalmol* **122**: 891–892.
- Sefton AJ, Dreher B (1985). Visual system. In: *The rat nervous system*, Vol 1. Paxinos G (ed). Academic Press: Sydney, Australia, pp 169–221.
- Sergott RC, Anand R, Belmont JB, Fischer DH, Bosley TM, Savino PJ (1989). Acute retinal necrosis neuropathy. Clinical profile and surgical therapy. *Arch Ophthalmol* **107**: 692–696.
- Silverstein BE, Conrad D, Margolis TP, Wong IG (1997). Cytomegalovirus-associated acute retinal necrosis syndrome. *Am J Ophthalmol* **123**: 257–258.
- Stroop WG, Schaefer DC (1986). Production of encephalitis restricted to the temporal lobes by experimental reactivation of herpes simplex virus. *J Infect Dis* **153**: 721–731.
- Stroop WG, Schaefer DC (1987). Severity of experimentally reactivated herpetic eye disease is related to the neurovirulence of the latent virus. *Invest Ophthalmol Vis Sci* **28**: 229–237.
- Stroop WG, Schaefer DC (1989). Neurovirulence of two clonally related herpes simplex virus type 1 strains in a rabbit seizure model. *J Neuropathol Exp Neurol* **48**: 171–183.
- Sun N, Cassell MD, Perlman S (1996). Anterograde, transneuronal transport of herpes simplex virus type 1 strain H129 in murine visual system. *J Virol* **70**: 5405–5413.
- Thompson WS, Culbertson WW, Smiddy WE, Robertson JE, Rosenbaum JT (1994). Acute retinal necrosis caused by reactivation of herpes simplex virus type 2. *Am J Ophthalmol* **118**: 205–211.
- Trejo LJ, Cicerone CM (1984). Cells in the pretectal olivary nucleus are in the pathway for direct light reflex of the pupil in the rat. *Brain Res* **300**: 49–62.
- Tusscher ten MPM, Klooster J, van der Want JLL, Lamers WPMA, Vrensen GFJM (1989). The allocation of nerve fibres to the anterior eye segment and peripheral ganglia of rats. I. The sensory innervation. *Brain Res* **494**: 95–104.
- Vann VR Jr. (1992). Selective spread of herpes simplex virus through the central nervous system in a murine model of the Acute Retinal Necrosis Syndrome. Ph.D. Dissertation, University of Miami, Coral Gables, FL.
- Vann VR, Atherton SS (1991). Neural spread of herpes simplex virus after anterior chamber inoculation. *Invest Ophthalmol Vis Sci* **32**: 2462–2472.
- Von Szily A (1924). Experimental endogenous transmission of infection from bulbus to bulbus. *Klin Monatsbl Augenheilkd* **75**: 593–602.
- Wander AH, Centifanto YM, Kaufman HE (1980). Strain specificity of clinical isolates of herpes simplex virus. *Arch Ophthalmol* **98**: 1458–1461.
- Wenisch HJC (1976). Retinohypothalamic projection in the mouse: Electron microscopic and ionophoretic

- investigations of hypothalamic and optic centers. *Cell Tissue Res* **167**: 547–561.
- Whittum JA, McCulley JP, Niederkorn JY, Streilein JW (1984). Ocular disease induced in mice by anterior chamber inoculation of herpes simplex virus. *Invest Ophthalmol Vis Sci* **25**: 1065–1073.
- Whittum-Hudson JA, Pepose JS (1987). Immunologic modulation of virus-induced pathology in a murine model of acute herpetic retinal necrosis. *Invest Ophthalmol Vis Sci* **28**: 1541–1548.
- Wolter JR (1960). Nerves of the normal human choroid. *Arch Ophthalmol* **64**: 120–124.
- Zemanick MC, Strick PL, Dix RD (1991). Direction of transneuronal transport of herpes simplex virus 1 in the primate motor system is strain-dependent. *Proc Natl Acad Sci USA* **88**: 8048–8051.
- Zhao M, Azumi A, Atherton SS (1995). T lymphocyte infiltration in the brain following anterior chamber inoculation of HSV-1. *J Neuroimmunol* **58**: 11–19.